

PLATE XVII.

- Fig. 1. Left lateral view of skull and mandible of a specimen of *Heloderma suspectum*, the latter disarticulated; life-size from the specimen (adult). *mx.*, maxillary; *pmx.*, premaxillary; *smx.*, septomaxillary; *ol.*, ossified dermal tubercles; *prf.*, prefrontal; *fr.*, frontal; *psf.*, post-frontal; *j.*, jugal; *pa.*, parietal; *co.*, columella; *pr.o.*, prootic; *sq.*, squamosal; *pl.*, pterygoid; *rz.*, vestige or rudiment of zygomatic arch; *q.*, quadrate; *d.*, dentary; *com.*, complementare; *cor.*, coronoidium; *ar.*, articulare; *an.*, angulare.
- Superior view of the right ramus of the mandible of *H. suspectum*. *op.*, operculare. Other letters as in Fig. 1.
 - Mesial aspect of the right ramus of the mandible of *H. suspectum*. Letters as in Fig. 1.
 - Superior aspect of the skull of *H. suspectum*, the mandible removed. *l.*, lacrymal; *l.c.*, lacrymal canal; *so.*, supraoccipital. Other letters as in Fig. 1.
 - Superior aspect of the skull of *H. horridum*, mandible removed. (After Bocourt.) Lettering as in Fig. 1.
 - Ventral aspect of the skull of *H. suspectum*, mandible removed; life size. *tt.*, teeth; *v.*, vomer; *pl.*, palatine; *tr.*, transpalatine (os transversum); *bs.*, basisphenoid; *btp.*, basipterygoid process; *eo.*, exoccipital; *bo.*, basioccipital. Other letters as in Fig. 1.

* PLATE XVIII.

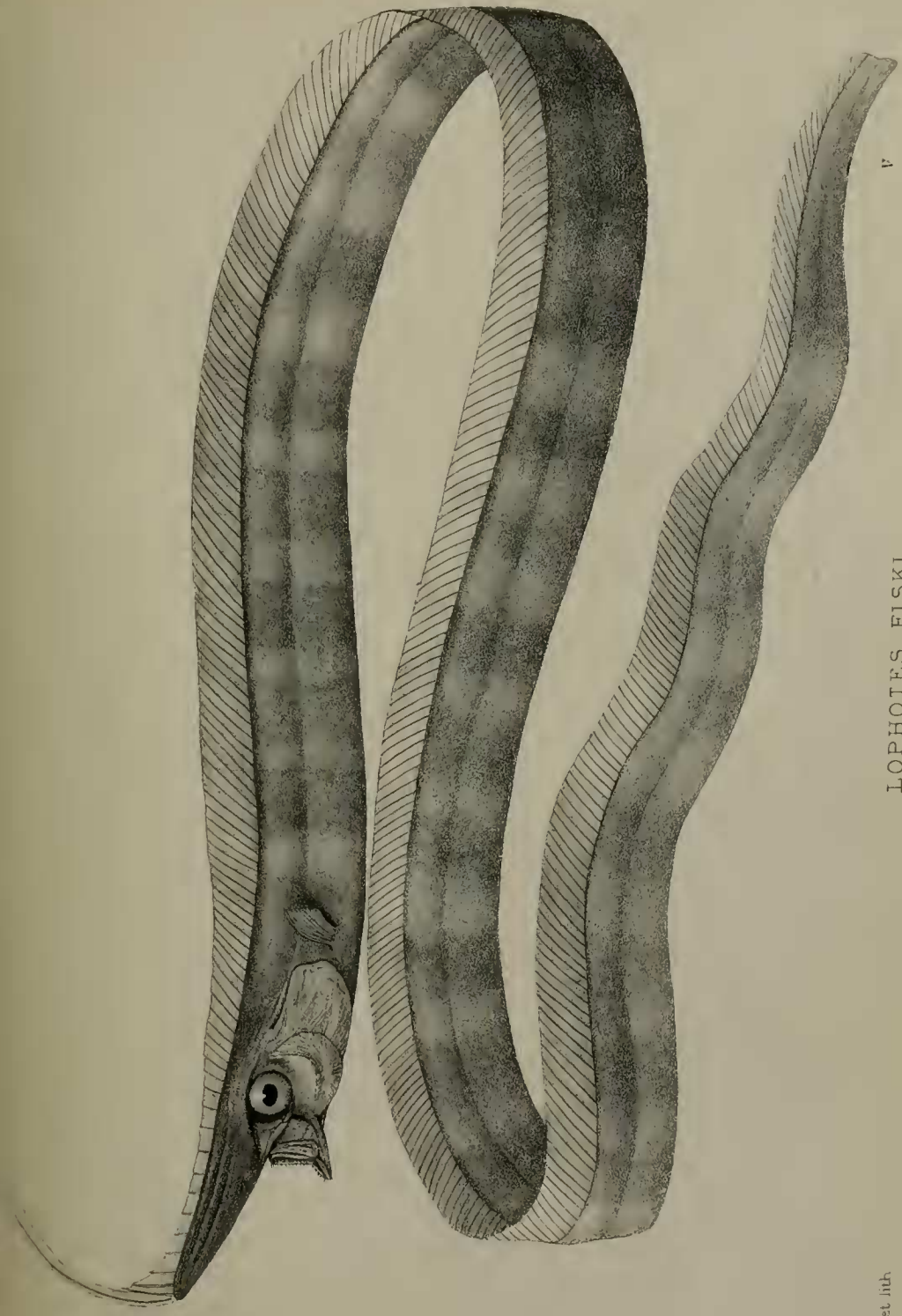
- Fig. 1. Dorsal aspect of the right pelvic limb of a specimen of *H. suspectum*, natural size. *f.*, femur; *p.*, patella; *t.*, tibia; *fb.*, fibula; *tfc.*, tibio-fibulare; *tr.*, distal tarsalia; *c.*, epiphysis on proximal extremity of metatarsal of the second toe.
- Ventral aspect of right humerus of a specimen of *H. suspectum*, natural size. *h.*, humerus.
 - Dorsal aspect of the antibrachium, carpus, and manus of the right pectoral limb of *H. suspectum*, natural size. *ul.*, ulna; *rd.*, radius; *uc.*, ulnare; *rc.*, radiale; *p.*, pisiforme; *c.*, centrale; *cp.*, distal carpalia.
 - Direct dorsal view of the pelvis and sacrum of *H. suspectum*, natural size. *pb.*, pubis; *of.*, foramen for the passage of the obturator nerve; *il.*, ilium; *f.cr.*, foramen cordiforme; *p.p.*, pectineal process; *is.*, ischium; *sv¹* and *sv²*, the two vertebræ that go to form the sacrum, the first and second respectively.
 - Ventral aspect of the sternum and shoulder-girdle and associated parts of *H. suspectum*, natural size. *s.*, scapula; *cl.*, clavicle; *co.*, coracoid; *ic.*, interclavicle; *st.*, sternum; *c.rb.*, costal ribs.
 - Ventral aspect of the hyoid arches of *H. suspectum*, somewhat enlarged. *b.hy.*, basihyal; *a.co.*, anterior cornua; *p.co.*, posterior cornua.

2. Description of a new Species of Deep-sea Fish from the Cape (*Lophotes fiski*). By Dr. A. C. L. GÜNTHER, F.R.S.

[Received March 14, 1890.]

(Plates XIX. & XX.)

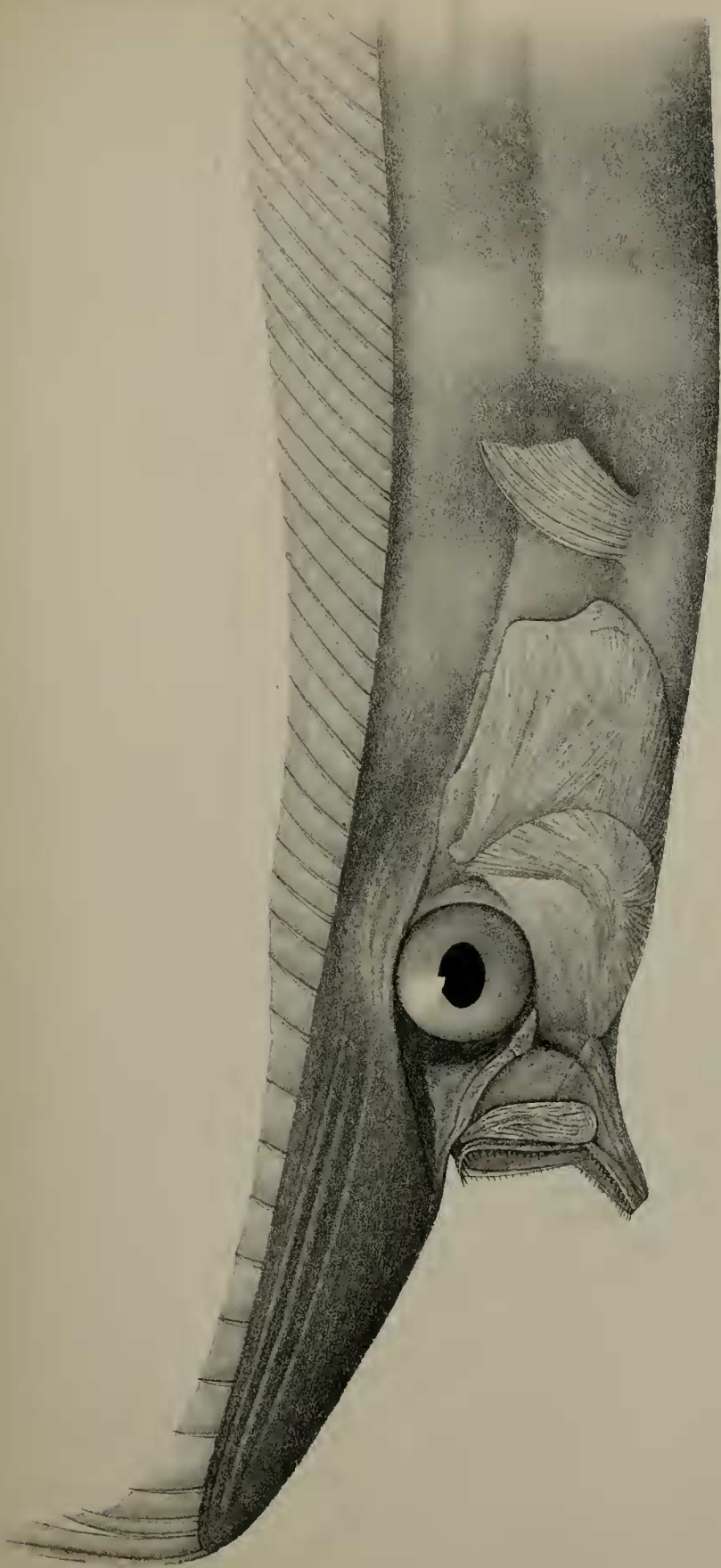
The Rev. G. H. R. Fisk, C.M.Z.S., has kindly submitted to my examination a highly interesting fish which proves to be a species of *Lophotes*, a genus still extremely rare in collections. In a letter addressed to our Secretary under date of September 9, 1889, Mr. Fisk says:—"Enclosed you will find a rough sketch of a fish which



LOPHOTES FISKI.

E. Minterm. del. et lith.

Minterm. Bros. imp.



R. Mintern del. et lith

HEAD OF LOPHOTES FISKI

Mintern Brics imp